PDR: A New Anti-VEGF Era?

2

WRITERS Associate Professor Adrian Fung and Dr. Michelle Hui

Proliferative diabetic retinopathy is a leading cause of severe vision impairment. Untreated, almost half of patients with high risk PDR will develop severe visual loss within five years.

Over the last few years, major studies have challenged conventional wisdom on the management of proliferative diabetic retinopathy (PDR). At the forefront of this paradigm shift has been debate revolving around the role of intravitreal anti-vascular endothelial growth factor (VEGF) agents for PDR. Globally, 8.5 per cent (422 million people) of the adult population suffer from diabetes mellitus (DM), a four-fold increase since the 1980s.[1] This trend relates to the positive correlation between DM and ageing. There is also a growing trend of adolescents developing DM due to obesity.

In Australia, the prevalence of DM has doubled from 2.4 per cent (400,000 people) in 1995 to approximately 5.1 per cent (1.2 million people) in 2014-15, with a daily rate of over 270 Australians being newly diagnosed with diabetes.[2,3] The prevalence differs between location and demographics, with a higher frequency in remote areas (6.7 per cent) than in major cities (4.7 per cent) and triple the rate in the indigenous Australian population.[2,4] The Australian Diabetes, Obesity and Lifestyle (AusDiab) study predicts that the prevalence of DM will continue to rise to 11.4 per cent by 2025.[5]

Diabetic retinopathy (DR) places a significant burden on the Australian economy, with an indirect cost of AU$2 billion per year from DR related vision loss.[2] In Australia, DR affects 24.5 per cent of people with known DM, with proliferative DR (PDR) accounting for 2.1 per cent of those with DM.[6] Proliferative diabetic retinopathy is a leading cause of severe vision loss in patients with DR.[7] Without treatment, almost half of patients with high risk PDR will develop severe visual loss within five years.[8]

PATHOGENESIS

The correlation between the pathogenesis of DR with chronic hyperglycemia, hypertension and hyperlipidemia is well established.[9] There are several pathways implicated with early DR, observed as changes in the cellular composition and structure of the microvasculature.[9] Damage to endothelial cells and retinal pericytes leads to a break down of the blood-retinal barrier. Progressive ischemia induces vascular endothelial growth factor (VEGF) which in turn stimulates the growth of new abnormal blood vessels, the hallmark of PDR. At any stage of DR, diabetic macular oedema (DMO) can occur.

CLASSIFICATION

Diabetic retinopathy can be classified by the International Clinical Disease Severity Scale for DR (Table 1).[10]

CLINICAL FEATURES

The hallmark of PDR is the presence of neovascularisation.[10-12] These abnormal blood vessels are stimulated by increased levels of VEGF in diabetic eyes and can develop at the

Table 1: International Clinical Disease Severity Scale for Diabetic Retinopathy (reproduced from Wilkinson CP, Ferris FL, 3rd, Klein RE, et al. Proposed international clinical diabetic retinopathy and diabetic macular edema disease severity scales. Ophthalmology 2003;110:1677-82)

Features on dilated eye examination	
No retinopathy	No microvascular lesions/ abnormalities
Mild non-proliferative diabetic retinopathy (NPDR)	Microaneurysms only
Moderate non-proliferative diabetic retinopathy	Microaneurysms and other microvascular lesions but not severe NPDR
Severe non-proliferative diabetic retinopathy	Not PDR, but any of following: ≥ 20 intra-retinal haemorrhages in four quadrants Venous beading in ≥ two quadrants Intra-retinal microvascular abnormalities in ≥ one quadrant
Proliferative diabetic retinopathy	One or more of the following: Neovascularisation of optics disc or elsewhere Preretinal/ vitreous haemorrhage

Associate Professor Adrian Fung

Dr. Michelle Hui

"for most patients presenting with PDR and DMO, anti-VEGF is first-line treatment"

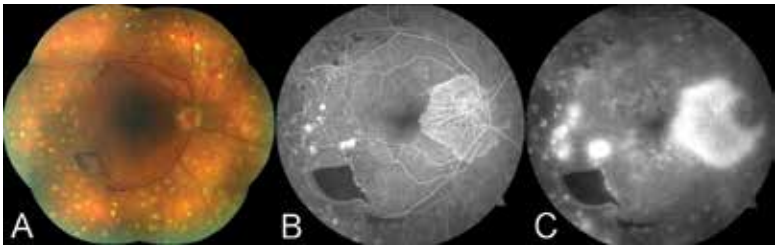

Figure 1. Colour fundus photograph of the right eye of a 57-year old Caucasian diabetic male, demonstrating neovascularisation at the disc (NVD) and panretinal photocoagulation scars (A). The NVD is much more prominent on fluorescein angiography at early (B) and late phases (C).

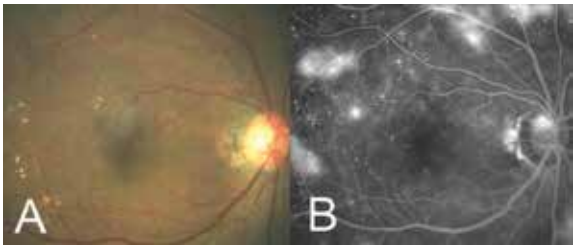

Figure 2. Colour fundus photograph of the right eye of a 45-year old Chinese male (A). The neovascularisation elsewhere is much easier to detect on fluorescein angiography (B). This also shows an enlarged foveal avascular zone.

optic nerve (neovascularisation of the disc, NVD, Figure 1), retina (neovascularisation elsewhere, NVE, Figure 2) or in the anterior segment (neovascularisation of the angle, NVA; neovascularisation of the iris, NVI). In the fundus, these vessels grow on top of the retina (pre-retinal), and often along the posterior hyaloid face and into the vitreous. This 'elevation' and their fine, lacy appearance can help distinguish nevoascularisation from intraretinal microvascular abnormalities (IRMAs). Gonioscopy is important to identify NVA and should be performed in patients at risk for PDR or with elevated intraocular pressures.

In themselves, neovascular vessels are usually asymptomatic. This can give patients a false sense of security as the absence of symptoms is discordant with the severity of their retinopathy. Examination of the peripheral fundus is necessary as eyes with mainly peripheral DR lesions have five times the risk of progressing to PDR[13,14] and peripheral NVE can easily be missed.

Neovascular vessels become symptomatic if they bleed into the pre-retinal space or vitreous. Any pre-retinal blood (which will obscure retinal blood vessels) warrants a careful examination for neovascularisation. Neovascular vessels can also fibrose and contract, leading to tractional and rhegmatogenous retinal detachments. Those in the angle can cause rubeotic glaucoma or hyphema. Independent to the proliferative process, diabetic patients can lose vision due to DMO or foveal ischaemia.

RISK FACTORS

The severity of retinopathy at baseline is the predominant risk factor for the progression of DR to high risk PDR.[15] Other risk factors include poor glycaemic control, systemic hypertension, dyslipidaemia, anemia, pregnancy, cataract surgery, diabetic neuropathy, low serum albumin, younger age, and Type 1 DM.[15]

INVESTIGATIONS

Systemic

All patients with diabetic retinopathy require systemic investigations performed in conjunction with their general practitioner and/or endocrinologist. These include fasting blood sugar level, HbA1c, systemic blood pressure, full blood count (for anemia), urea/electrolytes/creatinine (for diabetic nephropathy) and serum lipids. The presence of DR is a sign of widespread end-organ microcirculatory damage, and patients with DR have triple the risk of developing coronary artery disease and stroke, independent of cardiovascular risk factors.[16]

Ocular

Fluorescein Angiography

Although the presence of neovascularisation can usually be diagnosed clinically, fundus fluorescein angiography (FFA) is useful for confirming the presence of new vessels. Such vessels will demonstrate hyperfluorescent leakage in the late phases of the angiogram. Fundus fluorescein angiography is also useful in documenting areas of capillary non-perfusion and ischaemia, which are not easily identifiable with clinical examination alone. Such areas can be targeted when performing pan-retinal photocoagulation. Rarely, anterior segment angiography can be performed to identify NVI.

> "In patients presenting with PDR but no DMO, the recommended management is less clear"

Traditionally, seven-field montages captured with 30-50 degree cameras were the gold standard for fundus imaging in diabetic retinopathy.[17] More recently, ultra-widefield imaging systems have allowed for a field of view up to 200 degrees, and are thought to improve the detection of peripheral lesions and accuracy of classification (Figure 3).[17] Disadvantages of fluorescein angiography are its invasive nature and 5 per cent risk of developing an adverse reaction. This can range from mild (e.g. nausea, vomiting, pruritus, rash) to severe (e.g. local tissue necrosis, syncope, bronchospasm, anaphylaxis and cardiogenic shock).[18] Furthermore, recent evidence has shown that FFA may underestimate the vascular features of the retina by 50 per cent when compared to histological assessment.[19]

Optical Coherence Tomography Angiography

Optical coherence tomography (OCT) is the most important investigative tool for identifying DMO, but is not very effective in detecting proliferative disease other than cross-sectional characterisation of already identified neovascular lesions. OCT angiography (OCTA) is a newer technique based on OCT technology that produces 'en face' images. It detects variation (decorrelation) in reflectivity, phase shift or phase variance to identify blood flow within retinal vessels. Its basis is the principle that the only difference between sequentially obtained OCT cross sectional scans can be attributed to motion of erythrocytes (red blood cells) through retinal and choroidal blood vessels.[21]

Its advantages include an ability to visualise the retinal layers in segments ('en face'), identification of vascular complexes invisible to FFA (such as the deep capillary plexus and radial peripapillary capillary network), its high resolution, and the avoidance of an intravenous dye.[20]

Disadvantages include image artefacts such as from movement, masking and projection, its longer acquisition time than conventional FFA, smaller field of view, inability to show leakage and difficulties in interpreting this new technology.[22] OCT-A has been shown to be able to objectively stage DR.[23] Neovascular vessels do not 'leak' as they do in fluorescein angiography, but have two distinct morphologies: an irregular proliferation of fine vessels ('exuberant vascular proliferation') or pruned vascular loops.[24] Currently, the application of OCT-A in detecting proliferative diabetic retinopathy is limited by its small field of view.

MANAGEMENT

Systemic

Management of all diabetic retinopathy begins with systemic control of blood sugar levels[25,26] and systemic hypertension.[27] There is evidence that a 1 per cent decrease in glycated haemoglobin (HbA1c) can decrease progression to vision threatening retinopathy by 25 per cent.[28] Similarly, control of blood pressure helps reduce the risk of DR, with every 10mmHg decrease in blood pressure associated with a 15 per cent risk reduction

in PDR.[29] Treatment with fenofibrates may also reduce the progression of diabetic retinopathy and the need for laser, although whether this result is through its lipid lowering effect is debateable.[30,31]

Ocular

Laser (Panretinal Photocoagulation)

For forty years, panretinal laser photocoagulation (PRP) has been the gold standard treatment for PDR since the publication of two landmark clinical trials, the Diabetic Retinopathy Study (DRS)[8,32] and the Early Treatment Diabetic Retinopathy Study (ETDRS).[33] The aim of panretinal laser photocoagulation (PRP) is to elicit thermal damage in ischaemic extra-macular peripheral retina to reduce VEGF production and thus the neovascular drive (Figure 4).

Diabetic Retinopathy Study

The Diabetic Retinopathy Study (DRS) was a randomised controlled trial (RCT) that included 1,758 patients from 15 centres with PDR or severe bilateral non-proliferative diabetic retinopathy (NPDR). The two year incidence of severe visual loss (SVL; ie. visual acuity less than 6/240 at two or more consecutive four month followup visits) was reduced by over half in patients with PDR receiving PRP. The authors recommended PRP in eyes with 'high-risk' PDR; ie NVD or NVE associated with pre-retinal or vitreous haemorrhage, or NVD (within 1 disc diameter of the optic disc) with an area of at least one quarter to one third of the disc.

Early Treatment of Diabetic Retinopathy Study

The Early Treatment of Diabetic Retinopathy Study (ETDRS) randomised 3,711 patients with DR from 22 clinical centres. One eye from each patient was randomly assigned to early laser photocoagulation (mild or full), and the other eye did not receive laser. Full scatter laser photocoagulation consisted of 1,200-1,600 moderately intense white burns with a spot size of 500 microns and duration of 0.1s. Early photocoagulation was associated with a small reduction in the incidence of severe visual loss (visual acuity less than 6/240 at two consecutive visits), although the five-year rates of this were low in both groups (2.6 per cent in the laser arm, 3.7 per cent in the deferred laser arm).[33] Like DRS, ETDRS recommended prompt laser in patients with 'high risk' PDR.

Side Effects of Panretinal Photocoagulation

Both the DRS and ETDRS recognised that PRP is not without side effects, which can include: reduced peripheral vision, nyctalopia, reduced accommodation, pain, exacerbation of DMO, choroidal effusion, inadvertent foveal burn and late choroidal neovascularisation following an excessive burn. For this reason, PRP was not recommended for patients with mild or moderate NPDR.[8,33,34] The DRS found less side effects with argon compared to xenon laser photocoagulation.[8]

Newer Laser Photocoagulation Techniques

A recent Cochrane review compared conventional PRP described in the ETDRS (midperipheral scatter, moderate intensity PRP with 0.1 second pulse duration) with modern laser techniques (double frequency Nd: YAG laser; diode laser; longer laser pulse; less intense laser burns).[35] A total of 11 RCTs were included with best corrected visual acuity as the primary outcomes. The study found limited evidence for the efficacy and safety of these modern laser techniques compared to conventional PRP as described by the ETDRS.[35] The main limitation of the included RCTs was the high risk of bias and small study size – nine out of 11 studies had 50 or fewer subjects.

Intravitreal Anti-VEGF Therapy

Intravitreal anti-VEGF is an emerging treatment for PDR, with animal studies[36] and clinical trials[7,37,38] showing its efficacy in reducing retinal neovascularisation due to ischemia.

Diabetic Retinopathy Clinical Research Network Protocol S

The Diabetic Retinopathy Clinical Research Network (DRCRnet) Protocol S was a RCT of 394 PDR study eyes in 305 patients across 55 US clinical sites. It evaluated the intravitreal anti-VEGF agent ranibizumab against PRP with mean VA change at two years as the primary outcome.[7] Eyes with DMO could be included in either arm, and treatment with ranibizumab was allowed. Ranibizumab was found to be non-inferior to PRP with a mean VA improvement of +2.8 letters compared with +0.2 letters in the PRP group. In addition, eyes receiving ranibizumab had less visual field loss and were three times less likely to undergo vitrectomy or develop DMO.[7] However, the treatment regimen was intensive with a mean of seven anti-VEGF injections and monthly visits during the first year of the trial, while PRP was completed within one to three visits.

CLARITY

The CLARITY study was a single-blinded RCT comparing another anti-VEGF agent (aflibercept) with PRP in 232 patients with PDR but no DMO across 22 UK clinical sites.[37] Aflibercept was both non-inferior and superior to PRP, with mean best-corrected VA of 3.9 letters achieved and a median of four injections over one year. The aflibercept group had a significantly lower incidence of developing vitreous haemorrhage compared with the PRP group (9 per cent vs 21 per cent), but the proportion of patients requiring vitrectomy were small and not statistically significant between groups.[37]

Differences in the study design may explain why CLARITY showed superiority of anti-VEGF injection over PRP, while DRCRnet Protocol S did not. Aflibercept used in CLARITY has a higher binding affinity to VEGF than ranibizumab, and blocks VEGF-A, VEGF-B and placental growth factor (ranibizumab only blocks VEGF-A). CLARITY included patients with less severe PDR, no baseline DMO and 46 per cent had previous PDR treatment. On the other hand, DRCRnet Protocol S patients had a higher initial mean grade of retinopathy, 22-23 per cent had DMO at baseline and no patients had prior PRP.

PROTEUS

The PROTEUS study was a recent prospective, multi-centre RCT of 87 patients with high risk PDR comparing intravitreal ranibizumab plus PRP versus PRP alone.[38] A higher percentage of patients treated with ranibizumab plus PRP (92.7 per cent) had a reduction in 'neovascularisation total' (any decrease in the area of NV) compared with patients treated with PRP alone (70.5 per cent) at one year.[38] Furthermore, the mean number of PRP laser burns received in the ranibizumab plus PRP group was significantly lower than in the PRP alone group.[38]

Figure 3. Ultra-wide field fluorescein angiography demonstrates neovascularisation at the disc, elsewhere and extensive peripheral non-perfusion.

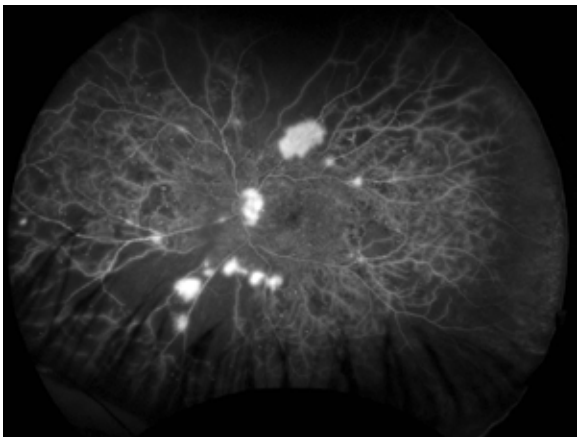

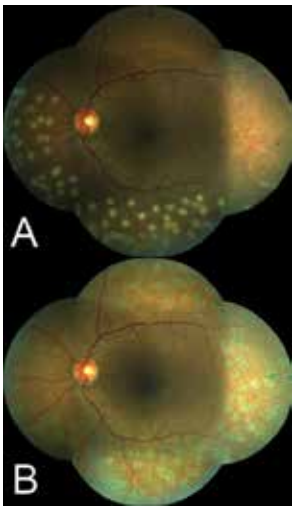

Figure 4. Recently applied panretinal photocoagulation (PRP) scars in a 38-year old female (A). The scars look white and the laser has been applied to the inferior retina first in case of vitreous haemorrhage, which tends to gravitate inferiorly. Five months later the PRP has been completed and the laser scars have become pigmented (B).

Panretinal Photocoagulation vs Intravitreal Anti-VEGF

There is ample evidence that intravitreal anti-VEGF is an effective treatment for DMO.[39-44] For this reason, for most patients presenting with PDR and DMO, anti-VEGF is first-line treatment. In patients presenting with PDR but no DMO, the recommended management is less clear.

Although CLARITY and PROTEUS suggest a benefit with anti-VEGF therapy, the disadvantages of intravitreal therapy (patient visits, cost, complications including endophthalmitis and systemic anti-VEGF exposure) must also be considered.[7,45] Intravitreal anti-VEGF can also be associated with acutely increased fibrosis and regression of the vascular component of fibrovascular proliferation, leading to tractional retinal detachment. In Australia, both ranibizumab and aflibercept are listed by the pharmaceutical benefits scheme for treatment of vision-affecting DMO, but not for PDR alone. Interestingly, there is emerging evidence that intravitreal anti-VEGF therapy may not only be useful in treating PDR and DMO, but may have a disease modifying effect by improving Diabetic Retinopathy Severity Scores.[46,47]

Future Targets

Beside anti-VEGF, other biochemical pathways underlying PDR are being investigated. A recent pilot study by Chang et al.[48] showed that the epiretinal membrane formation in PDR has a higher level of endothelin-1 levels compared to non-diabetic tissues via immunohistochemistry. Endothelin is a potent vasoconstrictor and ability to promote fibrosis is extensively studied in pulmonary studies.[48] Thus endothelin-1 can be a potential therapeutic target to prevent fibroblastic transition in PDR. Other promising targets include erythropoietin. Erythropoietin is produced in response to retinal ischemia with increased intraocular levels observed in PDR.[49] Animal studies have shown inhibition of erythropoietin decreases retinal neovascularisation.[49]

Vitrectomy Surgery

Vitrectomy surgery for PDR may need to be considered in the following situations:

- Non-clearing vision impairing vitreous haemorrhage
- Non-clearing vision impairing pre-macular haemorrhage (Figure 5)
- Tractional retinal detachment threatening the macula (Figure 6)
- Combined tractional and rhegmatogenous retinal detachment
- Visually significant epiretinal membrane

The aims of diabetic vitrectomy surgery are to clear vitreous and pre-macular haemorrhage, relieve retinal traction by segmentation and delamination, repair rhegmatogenous retinal detachment and remove visually significant epiretinal membranes. Separation of the posterior hyaloid of the vitreous from the retina removes the scaffold for proliferation of retinal new vessels. Supplemental PRP can often be added by endolaser, and in some cases silicone oil tamponade may be required for retinal detachment.

The indications and timing of vitrectomy for the management of advanced DR was assessed by the Diabetic Retinopathy Vitrectomy Study (DRVS) in 1985.[50] This RCT included a total of 616 eyes with severe (VA 6/240 or less) non-clearing (at least one month) diabetic vitreous haemorrhage and found that patients with Type 1 DM were more likely to recover desirable VA when vitrectomy was performed early (within several days of randomisation) rather than deferred (until one year after the onset of haemorrhage). Since the DRVS, modern small-gauge minimally invasive vitrectomy surgery (MIVS) has significantly reduced the morbidity and complication rates of vitrectomy surgery, and thus the threshold for intervention has also reduced. The intraoperative complication rates for diabetic vitrectomy surgery have been reported at 13.5 per cent without delamination and 30.4 per cent with delamination.[51] Overall, over 60 per cent of patients achieve 'visual success' (an improvement in vision of 0.3 logMAR or more, six to 12 months after surgery).[51]

CONCLUSION

PDR is a leading cause of severe vision impairment in patients with DM. Fundus fluorescein angiography, in particular with ultra-wide field imaging systems, is a useful adjuvant investigation to clinical examination. Although PRP laser photocoagulation has been the gold-standard for treatment of PDR, recent studies have shown intravitreal anti-VEGF to be at least non-inferior to PRP. Factors other than efficacy, including patient access, cost and complications may also need to be considered when individualising treatment. Vitrectomy surgery should be considered for non-clearing vitreous haemorrhage and tractional retinal detachment threatening the macula. mi

Associate Professor Adrian Fung, MBBS, MMed (Clin Epi), MMed (Ophthal Sci), FRANZCO is a specialist in Vitreoretinal Surgery and Medical Retina Diseases. He is Co-Director of the Westmead Hospital Vitreoretinal Fellowship, and works at Macquarie University Hospital, Retina & Macula

Figure 5. A large pre-macular haemorrhage in a 53-year old female seen on colour fundus photography (A) and optical coherence tomography, taken as a horizontal raster through the macula (B).

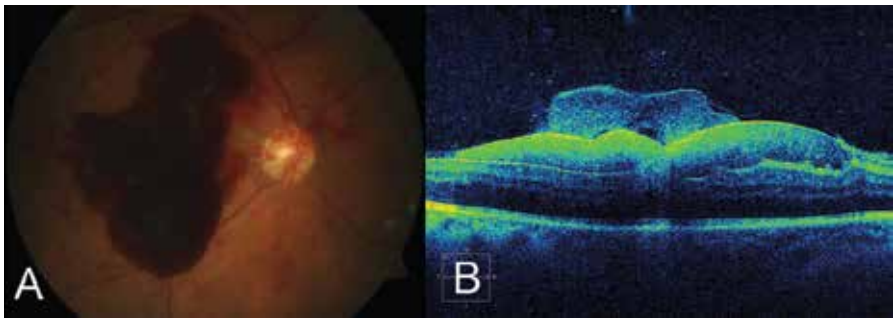

Figure 6. A 38-year old female presented with a right tractional retinal detachment threatening the macula and vitreous haemorrhage (A). The visual acuity was 6/12 as the fovea was still just attached. Vitrectomy surgery with membrane peeling and silicone oil tamponade was performed. At the one week post-operative visit, the patient's pin-hole visual acuity was 6/36 (B). The silicone oil was removed four months after surgery. One month after the second operation, the visual acuity had returned to 6/12 (C).

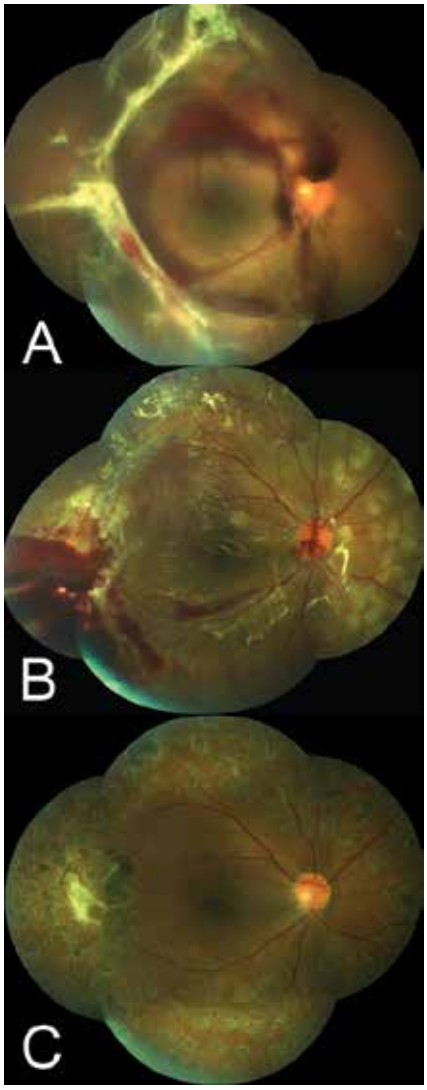

Specialists and Retina Associates in Sydney. A/Prof. Fung is active in research and teaching and has published over 50 international peer-reviewed journal articles and seven book or book chapters, including 'Ophthalmic Clinical Examination' and 'Vitreoretinal Surgery for Trainees'. He is a member of RANZCO, AAO, ANZSRS, ASRS, APVRS, ISOO, IntRis and the Vit Buckle Society and regularly lectures nationally and internationally. He is a chief investigator of the NHMRC funded Bionic Eye Project and teaches training ophthalmology registrars and fellows at Westmead Hospital. A/Prof. Fung is the course convenor for Ophthalmology Updates! (www.ophthalmologyupdates.com), an annual ophthalmology conference. He sits on the Sydney Eye Hospital Alumni Committee, Ophthalmic Research Institute of Australia Research Committee and RANZCO Clinical Standards Committee. A/Prof Fung has no financial disclosures relevant to the subject matter. www.dradrianfung.com.au

Dr. Michelle Hui, BMed, MD, completed medical school at the University of New South Wales in 2015. She is currently working as a senior resident and has experience in ophthalmic research and publications. She is interested in pursuing a career in ophthalmology.

To earn your CPD points from this article, answer the assessment available at mivision.com.au/ PDR-New-Anti-VEGF-Era

References

1. Organization WH. Global Report on Diabetes. Geneva, Switzerland: World Health Organization; 2016.

2. Statistics ABo. Diabetes Mellitus. Canberra, Australia: Australian Bureau of Statistics; 2015.

3. ELM Barr DM, PZ Zimmet, KR Polkinghorne, RC Atkins, DW Dunstan, SG Murray, JE Shaw. Tracking the accelerating epidemic: its causes and outcomes. International Diabetes Institute, Melbourne, Australia.: International Diabetes Institute; 2005.

4. Statistics ABo. Diabetes. Canberra, Australia: Australian Bureau of Statistics; 2013.

5. Williams ED, Rawal L, Oldenburg BF, Renwick C, Shaw JE, Tapp RJ. Risk of cardiovascular and all-cause mortality: impact of impaired health-related functioning and diabetes: the Australian Diabetes, Obesity and Lifestyle (AusDiab) study. Diabetes Care 2012;35:1067-73.

6. Tapp RJ, Shaw JE, Harper CA, et al. The prevalence of and factors associated with diabetic retinopathy in the Australian population. Diabetes Care 2003;26:1731-7.

7. Writing Committee for the Diabetic Retinopathy Clinical Research N, Gross JG, Glassman AR, et al. Panretinal Photocoagulation vs Intravitreous Ranibizumab for Proliferative Diabetic Retinopathy: A Randomized Clinical Trial. JAMA 2015;314:2137-46.

8. Photocoagulation treatment of proliferative diabetic retinopathy. Clinical application of Diabetic Retinopathy Study (DRS) findings, DRS Report Number 8. The Diabetic Retinopathy Study Research Group. Ophthalmology 1981;88:583-600.

9. Ciulla TA, Amador AG, Zinman B. Diabetic retinopathy and diabetic macular edema: pathophysiology, screening, and novel therapies. Diabetes Care 2003;26:2653-64.

10. Wilkinson CP, Ferris FL, 3rd, Klein RE, et al. Proposed international clinical diabetic retinopathy and diabetic macular edema disease severity scales. Ophthalmology 2003;110:1677-82.

11. Grading diabetic retinopathy from stereoscopic color fundus photographs–an extension of the modified Airlie House classification. ETDRS report number 10. Early Treatment Diabetic Retinopathy Study Research Group. Ophthalmology 1991;98:786-806.

12. Lechner J, O'Leary OE, Stitt AW. The pathology associated with diabetic retinopathy. Vision Res 2017;139:7-14.

13. Ferris FL, 3rd. The importance of peripheral diabetic retinopathy. Ophthalmology 2015;122:869-70.

14. Silva PS, Cavallerano JD, Haddad NM, et al. Peripheral Lesions Identified on Ultrawide Field Imaging Predict Increased Risk of Diabetic Retinopathy Progression over 4 Years. Ophthalmology 2015;122:949-56.

15. Davis MD, Fisher MR, Gangnon RE, et al. Risk factors for high-risk proliferative diabetic retinopathy and severe visual loss: Early Treatment Diabetic Retinopathy Study Report #18. Invest Ophthalmol Vis Sci 1998;39:233-52.

16. Cheung N, Wong TY. Diabetic retinopathy and systemic vascular complications. Prog Retin Eye Res 2008;27:161-76.

17. Falavarjani KG, Tsui I, Sadda SR. Ultra-wide-field Imaging in Diabetic Retinopathy. Vision Res 2017;139:187-90.

18. Kashani AH, Chen CL, Gahm JK, et al. Optical coherence tomography angiography: A comprehensive review of current methods and clinical applications. Prog Retin Eye Res 2017;60:66-100.

19. Mendis KR, Balaratnasingam C, Yu P, et al. Correlation of histologic and clinical images to determine the diagnostic value of fluorescein angiography for studying retinal capillary detail. Invest Ophthalmol Vis Sci 2010;51:5864-9.

20. Spaide RF, Klancnik JM, Jr., Cooney MJ. Retinal vascular layers imaged by fluorescein angiography and optical coherence tomography angiography. JAMA Ophthalmol 2015;133:45-50.

21. Ferrara D, Waheed NK, Duker JS. Investigating the choriocapillaris and choroidal vasculature with new optical coherence tomography technologies. Prog Retin Eye Res 2016;52:130-55.

22. Spaide RF, Fujimoto JG, Waheed NK. Image Artifacts in Optical Coherence Tomography Angiography. Retina 2015;35:2163-80.

23. Krawitz BD, Mo S, Geyman LS, et al. Acircularity index and axis ratio of the foveal avascular zone in diabetic eyes and healthy controls measured by optical coherence tomography angiography. Vision Res 2017;139:177-86.

24. Ishibazawa A, Nagaoka T, Yokota H, et al. Characteristics of Retinal Neovascularization in Proliferative Diabetic Retinopathy Imaged by Optical Coherence Tomography Angiography. Investigative Ophthalmology & Visual Science 2016;57:6247-55.

25. Anonymous. The effect of intensive diabetes treatment on the progression of diabetic retinopathy in insulin-dependent diabetes mellitus. The Diabetes Control and Complications Trial. Archives of Ophthalmology 1995;113:36-51.

26. Anonymous. Intensive blood-glucose control with sulphonylureas or insulin compared with conventional treatment and risk of complications in patients with type 2 diabetes (UKPDS 33). UK Prospective Diabetes Study (UKPDS) Group.[Erratum appears in Lancet 1999 Aug 14;354(9178):602]. Lancet 1998;352:837-53.

27. Anonymous. Tight blood pressure control and risk of macrovascular and microvascular complications in type 2 diabetes: UKPDS 38. UK Prospective Diabetes Study Group.[Erratum appears in BMJ 1999 Jan 2;318(7175):29]. Bmj 1998;317:703-13.

28. White NH, Sun W, Cleary PA, et al. Prolonged effect of intensive therapy on the risk of retinopathy complications in patients with type 1 diabetes mellitus: 10 years after the Diabetes Control and Complications Trial. Arch Ophthalmol 2008;126:1707-15.

29.Klein R, Knudtson MD, Lee KE, Gangnon R, Klein BE. The Wisconsin Epidemiologic Study of Diabetic Retinopathy: XXII the twenty-five-year progression of retinopathy in persons with type 1 diabetes. Ophthalmology 2008;115:1859-68.

30. Group AS, Group AES, Chew EY, et al. Effects of medical therapies on retinopathy progression in type 2 diabetes.[Erratum appears in N Engl J Med. 2011 Jan 13;364(2):190], [Erratum appears in N Engl J Med. 2012 Dec 20;367(25):2458]. New England Journal of Medicine 2010;363:233-44.

31. Keech AC, Mitchell P, Summanen PA, et al. Effect of fenofibrate on the need for laser treatment for diabetic retinopathy (FIELD study): a randomised controlled trial. Lancet 2007;370:1687-97.

32. Anonymous. Preliminary report on effects of photocoagulation therapy. The Diabetic Retinopathy Study Research Group. American Journal of Ophthalmology 1976;81:383-96.

33. Early photocoagulation for diabetic retinopathy. ETDRS report number 9. Early Treatment Diabetic Retinopathy Study Research Group. Ophthalmology 1991;98:766-85.

34. Mohamed Q, Gillies MC, Wong TY. Management of diabetic retinopathy: a systematic review. JAMA 2007;298:902-16.

35. Moutray T EJ, Lois N, Armstrong DJ, Peto T, Azuara-Blanco A. Different lasers and techniques for proliferative diabetic retinopathy. Cochrane Database of Systematic Reviews 2018.

36. Aiello LP, Avery RL, Arrigg PG, et al. Vascular endothelial growth factor in ocular fluid of patients with diabetic retinopathy and other retinal disorders. N Engl J Med 1994;331:1480-7.

37. Sivaprasad S, Prevost AT, Vasconcelos JC, et al. Clinical efficacy of intravitreal aflibercept versus panretinal photocoagulation for best corrected visual acuity in patients with proliferative diabetic retinopathy at 52 weeks (CLARITY): a multicentre, single-blinded, randomised, controlled, phase 2b, non-inferiority trial. Lancet 2017;389:2193-203.

38. Figueira J, Fletcher E, Massin P, et al. Ranibizumab Plus Panretinal Photocoagulation versus Panretinal Photocoagulation Alone for High-Risk Proliferative Diabetic Retinopathy (PROTEUS Study). Ophthalmology 2018.

39. Diabetic Retinopathy Clinical Research N, Wells JA, Glassman AR, et al. Aflibercept, bevacizumab, or ranibizumab for diabetic macular edema. New England Journal of Medicine 2015;372:1193-203.

40. Wells JA, Glassman AR, Ayala AR, et al. Aflibercept, Bevacizumab, or Ranibizumab for Diabetic Macular Edema: Two-Year Results from a Comparative Effectiveness Randomized Clinical Trial. Ophthalmology 2016;123:1351-9.

41. Bressler SB, Glassman AR, Almukhtar T, et al. Five-Year Outcomes of Ranibizumab With Prompt or Deferred Laser Versus Laser or Triamcinolone Plus Deferred Ranibizumab for Diabetic Macular Edema. American Journal of Ophthalmology 2016;164:57-68.

42. Nguyen QD, Brown DM, Marcus DM, et al. Ranibizumab for diabetic macular edema: results from 2 phase III randomized trials: RISE and RIDE. Ophthalmology 2012;119:789-801.

43. Korobelnik JF, Do DV, Schmidt-Erfurth U, et al. Intravitreal aflibercept for diabetic macular edema. Ophthalmology 2014;121:2247-54.

44. Heier JS, Korobelnik JF, Brown DM, et al. Intravitreal Aflibercept for Diabetic Macular Edema: 148-Week Results from the VISTA and VIVID Studies. Ophthalmology 2016;123:2376-85.

45. Yannuzzi NA, Sridhar J, Chang JS, Lin J, Kuriyan AE, Smiddy WE. Cost Evaluation of Laser versus Intravitreal Aflibercept for Proliferative Diabetic Retinopathy. Ophthalmology 2018;In Press.

46. Ip MS, Zhang J, Ehrlich JS. The Clinical Importance of Changes in Diabetic Retinopathy Severity Score. Ophthalmology 2017;124:596-603.

47. Ip MS, Domalpally A, Sun JK, Ehrlich JS. Long-term effects of therapy with ranibizumab on diabetic retinopathy severity and baseline risk factors for worsening retinopathy. Ophthalmology 2015;122:367-74.

48. Chang W, Lajko M, Fawzi AA. Endothelin-1 is associated with fibrosis in proliferative diabetic retinopathy membranes. PLoS One 2018;13:e0191285.

49. Watanabe D, Suzuma K, Matsui S, et al. Erythropoietin as a retinal angiogenic factor in proliferative diabetic retinopathy. N Engl J Med 2005;353:782-92.

50. Early vitrectomy for severe vitreous hemorrhage in diabetic retinopathy. Two-year results of a randomized trial. Diabetic Retinopathy Vitrectomy Study report 2. The Diabetic Retinopathy Vitrectomy Study Research Group. Arch Ophthalmol 1985;103:1644-52.

51. Jackson TL, Johnston RL, Donachie PHJ, Williamson TH, Sparrow JM, Steel DHW. The Royal College of Ophthalmologists' National Ophthalmology Database Study of Vitreoretinal Surgery. Report 6, Diabetic Vitrectomy. JAMA Ophthalmol 2016;134:79-85.